

# Small-incision lenticule extraction for correction of refractive error after 2 years of follow-up



## Authors:

Hassenien S. Shuber<sup>1</sup>   
Hussein A. Alhamami<sup>2</sup>   
Salah Z. Alasadi<sup>3</sup>

## Affiliations:

<sup>1</sup>Department of Surgery,  
College of Medicine,  
Mustansiriyah University,  
Baghdad, Iraq

<sup>2</sup>Department of Surgery, Kufa  
Medical College, University of  
Kufa, Najaf, Iraq

<sup>3</sup>Department of Surgery,  
Basra Medical College,  
University of Basra, Basra, Iraq

## Corresponding author:

Hassenien Shuber,  
hassanienshuber@gmail.com

## Dates:

Received: 10 July 2020  
Accepted: 08 Jan. 2021  
Published: 24 Feb. 2021

## How to cite this article:

Shuber HS, Alhamami HA,  
Alasadi SZ. Small-incision  
lenticule extraction for  
correction of refractive error  
after 2 years of follow-up. Afr  
Vision Eye Health. 2021;80(1),  
a596. [https://doi.org/  
10.4102/aveh.v80i1.596](https://doi.org/10.4102/aveh.v80i1.596)

## Copyright:

© 2021. The Author(s).  
Licensee: AOSIS. This work  
is licensed under the  
Creative Commons  
Attribution License.

## Read online:



Scan this QR  
code with your  
smart phone or  
mobile device  
to read online.

**Background:** Small-incision lenticule extraction (SMILE) is a relatively novel refractive procedure introduced to correct myopia and myopic astigmatism using femtosecond technology.

**Aim:** The aim of this study was to prospectively assess the predictability, efficacy and safety of SMILE surgery.

**Setting:** The study took place in Alyamama Vision Refractive Center, Baghdad, Iraq.

**Methods:** In this prospective, non-randomised, single-centre clinical study, all patients with myopia or myopic astigmatism underwent the SMILE procedure performed by one surgeon (H.S.S.) with a targeted post-operative refraction of 0 to  $-0.5$  dioptres (D). The procedure was performed using the VisuMax femtosecond platform. Post-operative data, including slit-lamp examination and measurements of uncorrected visual acuity (UCVA), best corrected visual acuity (BCVA), objective and subjective refraction, and intraocular pressure (IOP), were recorded.

**Results:** A total of 141 eyes of 76 patients (51 females and 25 males) were included in the study. The mean preoperative spherical equivalent (SE) ( $-4.37 \text{ D} \pm 1.65 \text{ D}$ ) ranged from  $-2.0 \text{ D}$  to  $-10.25 \text{ D}$  after 2 years of follow-up, and the mean post-operative SE ( $-0.06 \text{ D} \pm 0.18 \text{ D}$ ) ranged from  $-0.75 \text{ D}$  to  $0.63 \text{ D}$ . A UCVA of 20/40 or better was noted in 98% of the eyes at the 2-year follow-up. Most of the surgical complications, which were seen in 30 eyes, did not result in permanent visual loss. Corneal abrasion was the most common surgical complication, constituting 10.6% of all complications, followed by adherence of the lenticule to the cap (3.5%).

**Conclusion:** The SMILE procedure is effective with high safety and efficacy, and its complication rate will probably decrease with improvement in the surgeon experience level and refinement of the laser parameters.

**Keywords:** myopia; femto-SMILE; small-incision lenticule extraction; SMILE; astigmatism.

## Background

Laser-assisted *in situ* keratomileusis (LASIK) is considered a basic standard laser vision correction procedure for myopia and myopic astigmatism.<sup>1</sup> Small-incision lenticule extraction (SMILE) is a relatively new method for correcting myopia up to  $-12.0$  dioptres (D) and astigmatism up to  $-5.0$  D. This technology is currently only available from Carl Zeiss Meditec AG (Jena, Germany) and can be used for femtosecond lenticule extraction (FLEX) and SMILE. The first outcomes with FLEX were published in 2008, whilst the first outcomes with SMILE appeared in 2011.<sup>2,3</sup>

Small-incision lenticule extraction is a lamellar corneal procedure that became commercially available in 2012.<sup>2</sup> Removal of a volume of the central cornea has been achieved using different methods through the decades.<sup>4,5</sup> Small-incision lenticule extraction involves the removal of an intrastromal lenticule that is incised using a femtosecond laser; this lenticule is comparable to the tissue ablated with excimer laser in LASIK surgery.<sup>6</sup> Removal of the intracorneal lenticule can be achieved through meticulous dissection of the femtosecond pre-cut, and the lenticule is retrieved through a 3-mm – 4-mm incision.<sup>7</sup> The SMILE procedure is speculated to avoid some of the flap-related complications of LASIK, like flap displacement, traumatic flap dislocation and flap wrinkles.<sup>2</sup>

Small-incision lenticule extraction can also be used to avoid some of the limitations of photorefractive keratectomy (PRK), and it can be used in higher degree corrections, where regression and corneal haze are more probable with PRK.<sup>8</sup> Mitomycin-C as an adjunctive therapy

may decrease these complications, but PRK is preferred for smaller degrees of refractive errors. Small-incision lenticule extraction surgery provides the additional advantage of allowing completion of the procedure with a single machine, thus shortening the procedure time, decreasing the planned space required for installing the laser system and possibly enhancing patient comfort because the procedure is completed in one step.

The principal aim of this article is to assess how this relatively new technique can provide a safe and effective solution for correction of myopic and myopic astigmatic refractive errors.

## Patients and methods

This was a prospective, non-randomised, single-centre study performed over the period from January 2016 through February 2018 at Al-Yamama Vision Center, Baghdad, Iraq. Patients aged 18–48 years with myopia of  $-1$  D to  $-12$  D and astigmatism from  $-0.5$  D to  $-4$  D in otherwise healthy eyes that were free of comorbidities were included in this study after detailed ocular examinations. Consent was obtained from patients regarding participation in this study and for publication of the case details. The study adhered to the guidelines of the Declaration of Helsinki and received approval from the Ethics Committee of the Iraqi Ophthalmological Society.

Contact lens wear was discontinued at least a week before corneal topography and the surgical procedure. Preoperatively, all eyes were subjected to slit-lamp examination; dilated fundus assessment; intraocular pressure (IOP) evaluation; uncorrected visual acuity (UCVA); corrected distance visual acuity (CDVA); objective, manifest and cycloplegic refraction measurements; corneal topography with either a Galilei Dual Scheimpflug camera (Ziemer Ophthalmic Systems AG, Port, Switzerland) or Pentacam Scheimpflug topography (Oculus GmbH, Wetzlar, Germany) and pachymetry.

Eyes with thin corneas ( $\leq 480$   $\mu\text{m}$ ), unstable refraction (change of 0.5 D in less than 12 months), corneal ectasia, dry eye, scarred corneas or relevant ocular diseases were excluded from the study. All surgical procedures were performed under topical anaesthesia by the same surgeon (H.S.S.). The VisuMax femtosecond platform from Carl Zeiss Meditec was used at 500 kHz. The lenticule diameter was 6 mm – 6.5 mm, cap diameter was 7.1 mm – 7.6 mm and cap thickness was 110  $\mu\text{m}$  – 120  $\mu\text{m}$ . An access incision of 3 mm – 4 mm was created at  $110^\circ$  (the 11 o'clock position).

The eye was prepared with topical anaesthesia, and the skin was treated with povidone iodine (10%) at the beginning of the procedure. A screw speculum was placed, and the eye was opened whilst the patient was instructed to keep focusing on the blinking green target. The treatment was aimed on the visual axis, and the infrared camera with the machine was used frequently to further check for centration, particularly in dark-coloured eyes, where the centre of the pupil can be difficult to ascertain with the treatment view of the microscope. Suction was activated, and the laser was

applied using the fast mode of treatment. When the laser session ended, the eye was released from the suction ring, and dissection was started through an access wound using a blunt dissection spatula (Cilita Ltd., Ryazan, Russia). Initially, the cap and then the lenticular plane were dissected, and the released lenticule was retrieved through the 3.5-mm access wound. Antibiotics and steroid drops were applied and continued for 10–14 days thereafter. Ofloxacin 0.3% (Oflox®, Allergan, Dublin, Ireland) was applied six times per day for 10 days, and prednisolone acetate 1% (Pred Forte®, Allergan) was initially applied six times per day for 10 days and tapered 1 week later. Lubricating tear drops were applied as needed for 4–8 weeks.

The patients underwent a slit-lamp examination the day after the procedure to evaluate the corneal state, UCVA, CDVA, objective and subjective refraction, and IOP, and further assessments were performed at 1, 6, 9, 18 and 24 months. The data were collected and analysed using Data Graph software version 5.00c (Pieger, Germany).

## Ethical consideration

Approval to conduct the study was provided by the Ethical Board of the Iraqi Ophthalmological Society (research no. 131; ethical clearance no. 237b).

## Results

A total of 141 eyes from 76 patients were included in this study, including 51 female patients (101 eyes, 71.6%) and 25 male patients (40 eyes, 28.4%). The mean preoperative sphere was  $-3.8$  D  $\pm$  1.5 D (range,  $-1.0$  D to  $-10.0$  D). The mean preoperative cylinder value was  $-0.97$  D  $\pm$  0.94 D and ranged from 0.0 D to  $-4.0$  D. The mean preoperative spherical equivalent (SE) was  $-4.37$  D  $\pm$  1.65 D. Table 1 provides a summary of the preoperative average values and patient population.

The mean post-operative sphere was  $-0.05$  D  $\pm$  0.17 D (range,  $-0.75$  D to 0.75 D), and the mean post-operative cylinder was  $-0.03$  D  $\pm$  0.09 D (range, 0.00 D to  $-0.5$  D). The mean SE

**TABLE 1:** Preoperative average values in the patient population.

Variable	Values
<b>Age (years)</b>	
Mean	25
Range	18–48
<b>Gender</b>	
Female	101 eyes (71.6%)
Male	50 eyes (28.4%)
<b>Preoperative SE equivalent</b>	
Mean	$-4.37$ D $\pm$ 1.65 D
Range	$-2.0$ D to $-10.25$ D
<b>Preoperative sphere</b>	
Mean	$-3.88$ D $\pm$ 1.5 D
Range	1.0 D to $-10.0$ D
<b>Preoperative cylinder</b>	
Mean	$-0.97$ D $\pm$ 0.94 D
Range	0.00 D to $-4.0$ D

SE, spherical equivalent.

changed from  $-4.37 \text{ D} \pm 1.65 \text{ D}$  preoperatively to  $-0.06 \text{ D} \pm 0.18 \text{ D}$  post-operatively. Compliance with the follow-up visits at 2 years was 95.7%.

## Safety

As Figure 1 shows, at 9 months, 104 eyes (73.7%) had unchanged best corrected visual acuity (BCVA), 21 eyes (14.1%) gained one line, 10 eyes (7.0%) gained two lines and three eyes (2.1%) gained more than two lines. Three eyes (2.1%) lost one line and one eye (0.7%) lost more than one line of its BCVA. At 24 months, 92 eyes (68.6%) had unchanged BCVA, 23 eyes (17.1%) gained one line, 12 eyes (9.0%) gained two lines and two eyes (1.4%) gained more than two lines. Three eyes (2%) lost one line.

## Predictability

At 1 week post-operatively, the SE in 83% of the eyes was within 0.5 D and that in 86% of the eyes was within 1.0 D of the intended target. At 1 month, 89% of eyes had SE within 0.5 D and 100% had SE within 1.0 D of the intended refraction. At 18 months, 95% of the eyes had SD within 0.5 D and 96% had SD within 1.0 D of the intended target. At 24 months, 93% of the test eyes had SE within 0.5 D and 95% had SE within 1.0 D of the intended target (Figure 2).

The mean SE at 1 week post-operatively was  $-0.11 \text{ D} \pm 0.23 \text{ D}$  (range,  $-0.75 \text{ D}$  to  $0.63 \text{ D}$ ). At 1 month, the mean SE was 0.05

$\text{D} \pm 0.17 \text{ D}$ . At 18 months, the mean SE was  $-0.06 \text{ D} \pm 0.16 \text{ D}$ , and the mean SE at 24 months was  $-0.06 \text{ D} \pm 0.18 \text{ D}$  (range,  $-0.75 \text{ D}$  to  $0.63 \text{ D}$ ).

The post-operative SE showed proximity to the attempted target with an average deviation of  $0.00 \text{ D} - 0.75 \text{ D}$ , as shown in Figure 3.

## Efficacy

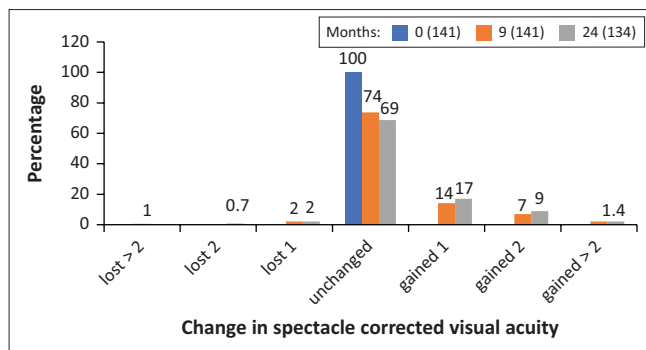
At 24 months, a UCVA of 20/40 was achieved in 98% of eyes, a UCVA of 20/30 or better was achieved in 91% of the eyes and a UCVA of 20/20 was obtained in 56% of the eyes (Figure 4).

## Stability

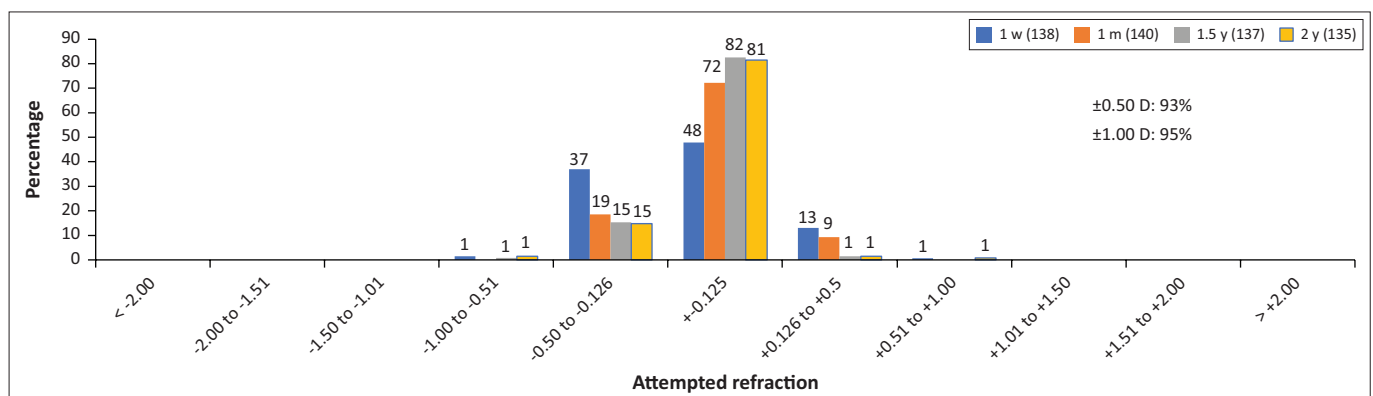
The first post-operative assessment of refraction was performed at the 1-week follow-up visit and throughout the follow-up period. A minor change in refraction was noted, as illustrated in Figure 5.

## Complications

*Corneal abrasions* occurred in 15 eyes (10.6%) and were the most common complication with SMILE. No bandage contact lenses were used for any of these cases. Intraoperative *suction loss* occurred in three eyes (2.1%), and the procedure was completed with redocking using the repair treatment software provided by the VisuMax laser machine. A small, visually insignificant tear of the access incision was seen in four eyes (2.8%), whilst adherence of the lenticule to the cap was encountered in five eyes (3.5%). Difficult dissection because of a *black spot area* was noted in two eyes (1.4%). Progressive *epithelial ingrowth* was noted in one eye (0.7%) and was managed using the circle therapy mode provided by the femtosecond machine to turn the cap to flap; the ingrowing epithelium was scraped off the bed and the back of the flap with adjunctive PRK for the back surface of the flap and the bed. The patient regained his BCVA and remained stable with no regrowth for the next 9 months of follow-up, as shown in Figure 6. No diffuse lamellar keratitis was recorded, although enhanced visibility of the interface



**FIGURE 1:** Safety in term of loss and gain in best spectacle corrected visual acuity at 0, 9 and 24 months.



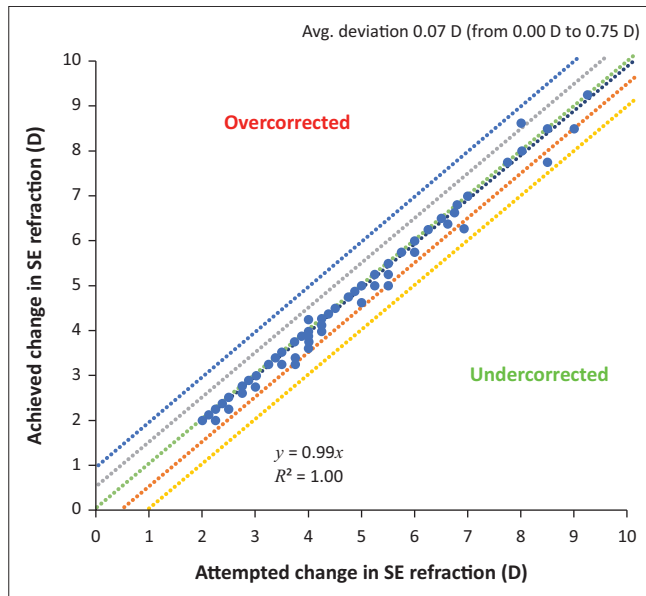
w, week; m, month; y, year.

**FIGURE 2:** Predictability of refractive outcome in term of spherical equivalent within  $\pm 0.5$  and  $\pm 1.0$  at 1 week, 1 month, 18 months and 2 years of follow-up. Refractive outcome in terms of percentage within attempted refraction.

was observed in the immediate post-operative visit 1 day after the procedure in three eyes.

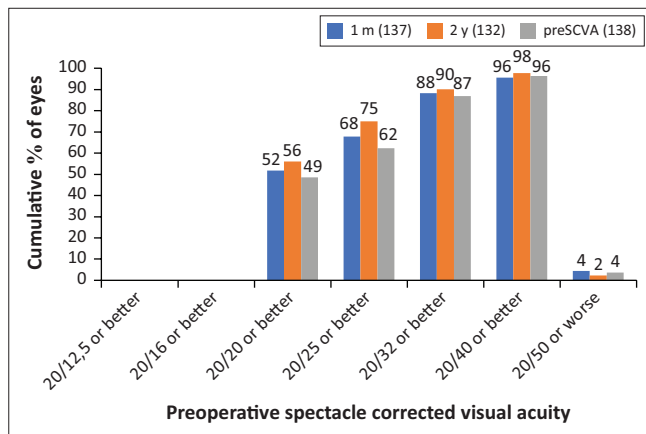
## Discussion

The femtosecond laser is becoming increasingly popular in refractive surgery, and it offers several advantages over mechanical microkeratomes.<sup>9</sup> In comparison with femto-



SE, spherical equivalent; D, dioptre; Avg., average.

**FIGURE 3:** Attempted versus achieved SE at 24 months. Scatter graph showing attempted versus achieved spherical equivalent 'predictability' of 135 eyes at 2-year post-operative follow up.



m, month; y, year; preSCVA, preoperative spectacle corrected visual acuity.

**FIGURE 4:** 'Efficacy' distribution of uncorrected visual acuity at 1 and 24 months. Pre-operative corrected distance visual acuity versus post-operative uncorrected distance visual acuity – Percentage.

**TABLE 2:** Complications of small-incision lenticule extraction surgery.

Complication (n = 30 eyes)	Number	Percentage
Corneal abrasion	15	10.6
Suction loss	3	2.1
Tear of the access incision	4	2.8
Adherence of the lenticule to the cap	5	3.5
Black spot area	2	1.4
Interface haze	3	2.1
Progressive epithelial ingrowth	1	0.7

LASIK, which is a well-established procedure, SMILE is a fairly new approach that has undergone several studies to evaluate various aspects related to its safety, efficacy, predictability and complications.

Small-incision lenticule extraction surgery can overcome the need for both excimer laser and femtosecond machines, reducing the space needed for the machines, decreasing the time and effort involved in the procedure and potentially reducing patient discomfort. The main issue with this relatively new surgical solution is the learning curve, which is longer than that for femto-LASIK.

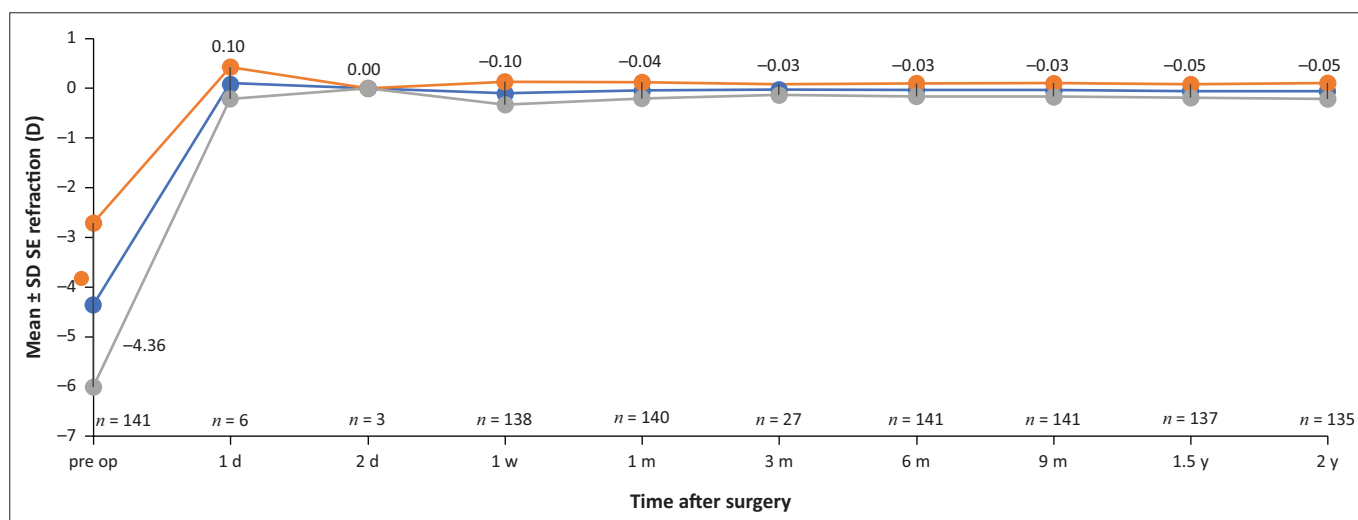
Small-incision lenticule extraction is performed with a small incision of 3 mm–4 mm, which necessitates the cutting of fewer corneal nerves and causes less dryness.<sup>10</sup> However, further studies are needed to validate this finding. The small wound also heals early, and because there is no flap, the risk of traumatic flap displacement is avoided, making the procedure particularly beneficial for those involved in a contact sport. Moreover, the duration of laser does not depend on the degree of refractive error as in the case of LASIK surgery.

In this study, a UCVA of 0.5 (20/40) was reported in 98% of the eyes, and 20/20 UCVA was noted in 56% of the eyes. Almost 97.6% of the eyes showed a UCVA of 20/40 or better in the study by Sekundo et al.<sup>6</sup> Shah et al.<sup>8</sup> and Moshirfar et al.<sup>5</sup> reported a UCVA of 20/40 or better in 95% of their study eyes and 20/20 or better in 62% of their eyes at the 6-month follow-up. These figures were very comparable to those obtained in our study, although our follow-up period was longer than those in the other studies.

Blum et al.<sup>8</sup> reported that 74% of their study eyes showed SE within 0.50 D of the intended correction, whilst 98% had SE within 1.00 D.<sup>8</sup> Shah et al.<sup>8</sup> reported that 91% of eyes had SE within 0.5 D and 100% had SE within 1.0 D of the intended correction at the 6-month follow-up. These figures are comparable to the outcomes of the present study.

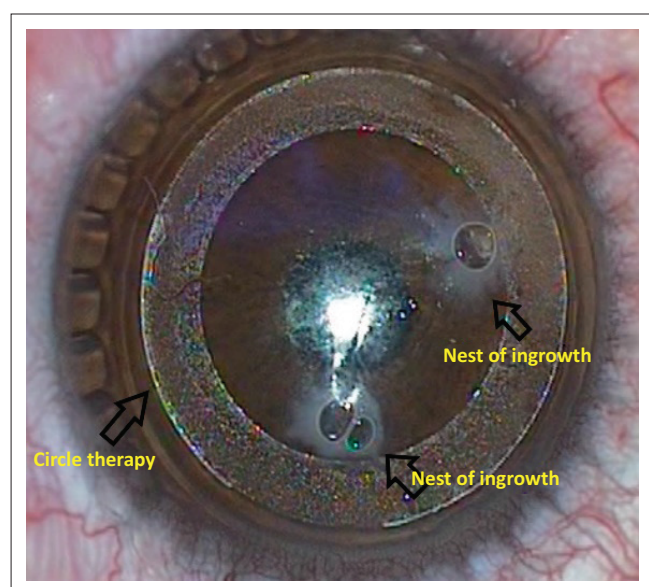
Ramirez-Miranda et al. reported a complication rate of 26.9% (43 eyes) in their series that included 160 eyes. The reported complications included epithelial defect (41%, 18 eyes), suction loss (11.6%, 5 eyes) and black spot (14%, 6 eyes).<sup>11</sup>

The most frequent complication encountered in our study was corneal abrasion. The epithelial defects in all cases were small and healed within 24 h without the need for bandage contact lens placement. Suction loss was seen less frequently in this group and probably occurred because of eye movement or excessive fluid that entered the suction port. Fortunately, in all three cases we faced, the lenticule cuts were already completed, and this provided the chance for redocking with the use of the 'repair' tool of the



SD, standard deviation; SE, spherical equivalent; d, day; w, week; m, month; y, year.

**FIGURE 5:** Stability of refraction over 24 months. Attempted versus achieved spherical equivalent over time 'stability'.



**FIGURE 6:** Two nests of epithelial ingrowth during circle therapy.

VisuMax laser to complete the procedures. Black spot with difficult dissection occurred less frequently in this study group in comparison with the study by Ramirez-Miranda et al.<sup>11</sup> Suction loss is still a common complaint amongst surgeons and is related at least, in part, to the weak suction setting of the VisuMax platform. In this study, suction loss mostly occurred in the early cases; however, the meticulous drying of the conjunctival sac and encouraging the patient to stay calm during the laser session may have resulted in a considerable reduction in the occurrence of this event.

An increasing epithelial ingrowth was seen in one eye and necessitated turning the cap into a flap with 'circle therapy', a tool provided by Carl Zeiss Meditec, in which the ingrowth with PTK on both the flap back surface and the stromal bed was removed, and the patient regained his pre-ingrowth visual acuity with no recurrence of the disorder through

9 months of follow-up thereafter. Most complications were related to the learning curve, and their rate of occurrence decreased over time.

## Conclusion

Small-incision lenticule extraction is a predictable, effective and safe procedure for treating myopia and myopic astigmatism and shows good stability of refractive outcomes. The learning curve was associated with an increased rate of complications initially, and these decreased in general as the surgeon's experience improved.

## Acknowledgements

Technician Mustafa Safa Shuber participated in the process of preoperative evaluation of patients and reassessment during the follow-up period. Optician Haider Rasan was responsible for assessing the refractive errors preoperatively and then after the procedure.

## Competing interests

The authors declare that they have no financial or personal relationships that may have inappropriately influenced them in writing this research article.

## Authors' contributions

H.S.S., H.A.A. and S.Z.A. contributed equally to this work.

## Funding information

This research received no specific grant from any funding agency in the public, commercial or not-for-profit sectors.

## Data availability

Data sharing is not applicable to this article.

## Disclaimer

The views and opinions expressed in this article are those of the authors and do not necessarily reflect the official policy or position of any affiliated agency of the authors.

## References

1. Baily MD, Zadnik K. Outcomes of LASIK for myopia with FDA-approved lasers. *Cornea*. 2007;26(3):246–254. <https://doi.org/10.1097/ICO.0b013e318033dbf0>
2. Agca A, Demirok A, Yildirim Y, et al. Refractive lenticule extraction (ReLEx) through a small incision (SMILE) for correction of myopia and myopic astigmatism: Current perspectives. *Clin Ophthalmol*. 2016;10:1905–1912. <https://doi.org/10.2147/OPTH.S80412>
3. Sekundo W, Kunert K, Russmann C, et al. First efficacy and safety study of femtosecond lenticule extraction for the correction of myopia: Six month results. *J Cataract Refract Surg*. 2008;34(9):1513–1520. <https://doi.org/10.1016/j.jcrs.2008.05.033>
4. Burazovitch J, Naguzeswski D, Beuste T, Guillard M. [Visual outcomes four years after small incision lenticule extraction (SMILE) surgery on highly myopic eyes [French version]]. *J Fr Ophthalmol*. 2017;40(7):561–570. <https://doi.org/10.1016/j.jfo.2017.01.014>
5. Moshirfar M, Murri MS, Shah TJ, et al. Initial single-site surgical experience with SMILE: A comparison of results to FDA SMILE, and the earliest and latest generation of LASIK. *Ophthalmol Ther*. 2018;7(2):347–360. <https://doi.org/10.1007/s40123-018-0137-7>
6. Sekundo W, Kunert KS, Blum M. Small incision corneal refractive surgery using the small incision lenticule extraction (SMILE) procedure for the correction of myopia and myopic astigmatism: Results of a 6 month prospective study. *Br J Ophthalmol*. 2011;95(3):335–339. <https://doi.org/10.1136/bjo.2009.174284>
7. Hamed AM, Abdelwahab SM, Soliman TT. Intraoperative complications of refractive small incision lenticule extraction in the early learning curve. *Clin Ophthalmol*. 2018;12:665–668. <https://doi.org/10.2147/OPTH.S157356>
8. Shah R, Shah S, Sengupta S. Results of small incision lenticule extraction: All-in-one femtosecond laser refractive surgery. *J Cataract Refract Surg*. 2011;37(1):127–137. <https://doi.org/10.1016/j.jcrs.2010.07.033>
9. Binder PS. Flap dimensions created with the IntraLase FS laser. *J Cataract Refract Surg*. 2004;30(1):26–32. [https://doi.org/10.1016/S0886-3350\(03\)00578-9](https://doi.org/10.1016/S0886-3350(03)00578-9)
10. Ganesh S, Brar S, Arra RR. Refractive lenticule extraction small incision lenticule extraction: A new refractive surgery paradigm. *Indian J Ophthalmol*. 2018;66(1):10–19. [https://doi.org/10.4103/ijo.IJO\\_761\\_17](https://doi.org/10.4103/ijo.IJO_761_17)
11. Ramirez-Miranda A, Ramirez-Luquin T, Navas A, Graue-Hernandez EO. Refractive lenticule extraction complications. *Cornea*. 2015;34:S65–S67. <https://doi.org/10.1097/ICO.0000000000000569>